



<b>DATE</b>	<b>RESENTING CLINICAL SIGNS</b>
4/13/23	History: Previous echos showed TVD, PH, and possible VSD. Receiving enalapril 1.25 mg BID, sildenafil 4 mg TID, and clopidogrel 18.75 mg SID. Grade 5/6 murmur. Doing well.
<b>PERFORMED BY:</b>	<b>ECHOCARDIOGRAPHIC FINDINGS</b>
Loetitia Saint-Jacques, RVT, LVT	2D, M-mode, and Doppler study. This exam is compared to the one performed 4/6/22.
<b>INTERPRETED BY</b>	There is moderate left atrial dilation. The mitral valve appears normal, though trace mitral regurgitation is present. Left ventricular wall thickness is normal. There is mild left ventricular dilation. Left ventricular systolic function is normal. A left-to-right shunting perimembranous ventricular septal defect is present. The aorta and aortic valve are normal. There is moderate right atrial and mild right ventricular dilation. The tricuspid valve leaflets are thickened, and there is Doppler evidence of tricuspid regurgitation present. TR velocity is consistent with the presence of severe pulmonary hypertension (86 mmHg / prev. PG 111 mmHg). The pulmonary artery and pulmonic valve appear normal, though there is increased flow velocity in the main pulmonary artery. No shunting lesions are visualized. No pericardial effusion or cardiac masses are seen.
Keith Blass, DVM, MS, DACVIM (Cardiology)	
<b>PATIENT</b>	LA - 19.8 mm (prev. 16.3 mm)
Starfruit NHS	IVSd - 4.3 mm (prev. 4.3 mm)
	LVPWd - 4.3 mm (prev. 4.3 mm)
	LVIDd - 20.8 mm (prev. 21.2 mm)
	LVIDs - 10.5 mm (prev. 12.5 mm)
<b>SPECIES</b>	FS - 49.5% (prev. 41%)
Feline	RA - 16.7 mm (prev. 16.7 mm)
	LVOT - 1.80 m/s (prev. 1.57 m/s)
	RVOT - 3.53 m/s (prev. 3.16 m/s)
	TR - 4.64 m/s (prev. 5.27 m/s)
	VSD - 3.28 m/s (prev. 3.28 m/s)
<b>BREED</b>	
DSH	<b>RADIOGRAPHIC FINDINGS</b>
	Orthogonal thoracic radiographs are submitted for review.
<b>SEX</b>	There is moderate enlargement of the cardiac silhouette. The pulmonary vessels are within normal limits. The pulmonary parenchyma and pleural space are within normal limits. The trachea is normal. The remainder of the thorax is unremarkable.
FS	
<b>ASSESSMENT/RECOMMENDATIONS</b>	
<b>AGE</b>	Tricuspid valve dysplasia (TVD)
21 mo	Pulmonary hypertension
	Ventricular septal defect (VSD)
<b>WEIGHT</b>	This examination is similar to the one performed one year ago, with the exception that Starfruit now has moderate dilation of her left atrium. Given this, Starfruit's risk for the development of left-sided congestive heart failure has increased (no evidence of CHF is currently seen in her radiographs), and careful monitoring of her respiratory rate/effort is recommended. Given the continued presence of severe pulmonary hypertension and moderate right heart chamber dilation, Starfruit continues to be at high risk for the development of right-sided congestive heart failure, pulmonary thromboembolism, and/or arrhythmia formation, therefore, careful monitoring for signs associated with these conditions is also recommended.
8 lb	
<b>HOSPITAL NAME</b>	
Nevada Humane Society	No change in therapy is recommended at this time as long as Starfruit remains asymptomatic.
<b>REFERRING VET</b>	A recheck echocardiogram is recommended in 6 months. Repeat thoracic/abdominal radiographs are recommended if clinical signs suggestive of the presence of pulmonary edema, pleural and/or
Dr. Matzke	



DATE peritoneal effusion develop.

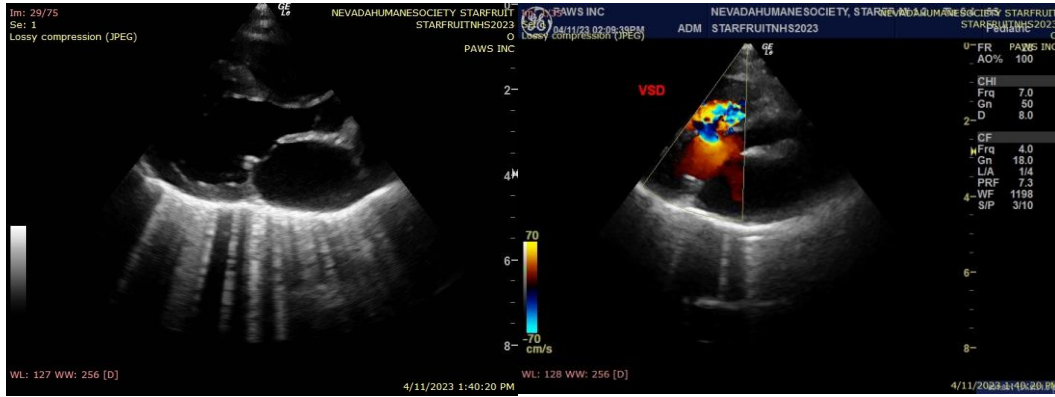
4/13/23

PERFORMED BY:

Loetitia Saint-Jacques, RVT, LVT

INTERPRETED BY

Keith Blass, DVM, MS, DACVIM (Cardiology)



PATIENT

Starfruit NHS

The information and recommendations provided are based on the images presented by the referring veterinarian. No evaluation can be communicated regarding pathology that was not visible in the image/video clips provided.

Thank you for this referral. If the clinical or image interpretation does not parallel your findings or if I can be of any further assistance please contact me.

SPECIES

Feline

Keith Blass, DVM, MS, DACVIM (Cardiology)  
KeithBlass@gmail.com  
631-804-5754

BREED

DSH

SEX

FS

AGE

21 mo

WEIGHT

8 lb

HOSPITAL NAME

Nevada Humane Society

REFERRING VET

Dr. Matzke